

---

## Special Topic

---

# International Clinical Recommendations on Scar Management

**Thomas A. Mustoe, M.D., Rodney D. Cooter, M.D., Michael H. Gold, M.D., F. D. Richard Hobbs, F.R.C.G.P., Albert-Adrien Ramelet, M.D., Peter G. Shakespeare, M.D., Maurizio Stella, M.D., Luc Téot, M.D., Fiona M. Wood, M.D., and Ulrich E. Ziegler, M.D., for the International Advisory Panel on Scar Management**

*Chicago, Ill., Nashville, Tenn., Adelaide, South Australia, and Perth, Western Australia, Australia, Birmingham and Salisbury, United Kingdom, Lausanne, Switzerland, Turin, Italy, Montpellier, France, and Wurzburg, Germany*

Many techniques for management of hypertrophic scars and keloids have been proven through extensive use, but few have been supported by prospective studies with adequate control groups. Several new therapies showed good results in small-scale trials, but these have not been repeated in larger trials with long-term follow-up. This article reports a qualitative overview of the available clinical literature by an international panel of experts using standard methods of appraisal. The article provides evidence-based recommendations on prevention and treatment of abnormal scarring and, where studies are insufficient, consensus on best practice. The recommendations focus on the management of hypertrophic scars and keloids, and are internationally applicable in a range of clinical situations. These recommendations support a move to a more evidence-based approach in scar management. This approach highlights a primary role for silicone gel sheeting and intralesional corticosteroids in the management of a wide variety of abnormal scars. The authors concluded that these are the only treatments for which sufficient evidence exists to make evidence-based recommendations. A number of other therapies that are in common use have achieved acceptance by the authors as standard practice. However, it is highly desirable that many standard practices and new emerging therapies undergo large-scale studies with long-term follow-up before being recommended conclusively as alternative therapies for scar management. (*Plast. Reconstr. Surg.* 110: 560, 2002.)

The management of hypertrophic scars and keloids is characterized by a wide variety of techniques. Many have been proven through extensive use over the past two decades, but few have been supported by prospective studies with adequate control groups, and in some cases even safety data are lacking. Many new

therapies showed early promise in small-scale trials, but these results have not been repeated in larger trials with long-term follow-up. Judgment of efficacy has further been limited by the difficulty in quantifying change in scar appearance, and by the natural tendency for scars to improve over time. Thus, cutaneous scar management has relied heavily on the experience of practitioners rather than on the results of large-scale randomized, controlled trials and evidence-based techniques.

This article reports a qualitative overview of over 300 published references using standard methods of appraisal and, where studies are insufficient, expert consensus on best practices from an international group with extensive experience and interest in the treatment of scarring. Although focusing primarily on the management of hypertrophic scars and keloids, the recommendations are internationally applicable in a range of clinical situations.

### DATA COLLECTION

An initial systematic MEDLINE and EMBASE search (1996 through 2001) took place using the mesh terms “scar treatments,” “surgery,” “silicone gel sheeting,” “intralesional corticosteroids,” “radiotherapy,” “cryotherapy,” “pressure therapy,” and “laser therapy.” In addition, a search on scar evaluation methods took place and all review articles on the management of hypertrophic scars and keloids were accessed in these data-

From Northwestern University School of Medicine, Royal Adelaide Hospital and The Queen Elizabeth Hospital, Gold Skin Care Centre, University of Birmingham, Laing Burn Research Laboratories, Salisbury District Hospital, Burn Centre, CTO, Burns Unit University Hospital Lapeyronie, Chirurgische Universitätsklinik, Burns Unit, and Royal Perth Hospital and Princess Margaret Children's Hospitals. Received for publication March 20, 2001; revised December 6, 2001.

bases. A secondary hand search of citations in the accessed articles was also conducted.

The authors provided additional review articles, clinical studies, and recent unpublished data that revealed further useful cited references in English and other languages. Those references providing original data on the efficacy of scar management techniques were graded according to "hierarchy of evidence" methods to reflect the reliability of data.<sup>1-3</sup> The drafts of the manuscript were reviewed by the chairman and panel during a series of teleconferences and by e-mail.

#### CLASSIFICATION

Scar classification schemes need to be as clinically relevant as possible, and the authors have extended standard terminology for this article (Table I).

#### GRADING SYSTEMS

A number of grading systems have been suggested over recent years.<sup>4-7</sup> The most widely used system is the Vancouver Scar Scale,<sup>8-10</sup> which provides an objective measurement of burn scars and assists prognosis and management. Generic measurement tools and record

TABLE I  
Scar Classification

---

Mature scar—A light-colored, flat scar.
Immature scar—A red, sometimes itchy or painful, and slightly elevated scar in the process of remodeling. Many of these will mature normally over time and become flat, and assume a pigmentation that is similar to the surrounding skin, although they can be paler or slightly darker.
Linear hypertrophic (e.g., surgical/traumatic) scar—A red, raised, sometimes itchy scar confined to the border of the original surgical incision. This usually occurs within weeks after surgery. These scars may increase in size rapidly for 3–6 months and then, after a static phase, begin to regress. They generally mature to have an elevated, slightly rope-like appearance with increased width, which is variable. The full maturation process may take up to 2 years.
Widespread hypertrophic (e.g., burn) scar—A widespread red, raised, sometimes itchy scar that remains within the borders of the burn injury.
Minor keloid—A focally raised, itchy scar extending over normal tissue. This may develop up to 1 year after injury and does not regress on its own. Simple surgical excision is often followed by recurrence. There may be a genetic abnormality involved in keloid scarring. Typical sites include earlobes.
Major keloid—A large, raised (>0.5 cm) scar, possibly painful or pruritic and extending over normal tissue. This often results from minor trauma and can continue to spread over years.

---

forms have been developed to help use this scale.

#### PREVENTION OR TREATMENT

It is much more efficient to prevent hypertrophic scars than to treat them. Prevention implies using a therapy with the aim of reducing the risk of a problem scar evolving. The transition to a treatment regimen takes place when a true hypertrophic scar or keloid, and not an immature scar, is diagnosed. Conceptually and practically, treatment and prevention regimens can be similar, and the following section presents the clinical data for both. Early diagnosis of a problem scar can considerably impact the outcome. The consensus of the authors is that the most successful treatment of a hypertrophic scar or keloid is achieved when the scar is immature but the overlying epithelium is intact, although this is not as yet confirmed in current literature.

#### THERAPIES

A comprehensive review of the clinical literature published over the past 30 years on scar treatments was undertaken and the evidence was graded for quality. An evaluation is presented for each modality. The efficacy of two scar management techniques, silicone gel sheeting and injected corticosteroids, has been demonstrated in randomized, controlled trials.

Comparison between treatment modalities and between clinical studies is difficult, as defining an adequate response to therapy remains a relatively neglected area. A mild partial response, which may still leave a cosmetically unacceptable scar, is accepted as a therapeutic success in most studies. Scars never disappear and in many cases only partial response is possible.

The variability in efficacy and recurrence rates between studies is striking and makes single uncontrolled studies impossible to evaluate. There are some good reasons for this variability. First, differentiating hypertrophic scars from keloids can be problematic. Second, there is a tremendous range between the scar that becomes hypertrophic in the first few months and then completely resolves with little or no treatment and the more severe hypertrophic scar that becomes permanently disfiguring. Length of follow-up, heterogeneity of the scars, and the lack of controls can either overestimate or understate the benefit of treatment, but more often the former. Third, ke-

loids often do not recur for 6 months to as long as 2 years, and so length of follow-up is critical. Very few studies on keloids have adequate follow-up. These limitations must be kept in mind in evaluating any of the therapies below.

### *Surgery*

Surgical excision of hypertrophic scars or keloids is a common management option when used in combination with steroids and/or silicone gel sheeting. However, excision alone of keloids results in a high rate of recurrence (45 to 100 percent).<sup>11-14</sup>

Combining surgery with steroid injections reduces the recurrence rate of keloids to less than 50 percent, with the combination of surgery and perioperative radiation therapy reducing recurrence to 10 percent.<sup>11,15</sup> However, this combination approach is usually reserved for abnormal scars resistant to other treatments.

Hypertrophic scarring resulting from excessive tension or wound complications, such as infection or delay in healing, can be treated effectively with surgical excision combined with surgical taping and silicone gel sheeting. Scars that are subject to tension require substantial physical support. The authors agreed that the most effective way of splinting scars is by surgical closure with intradermal sutures for at least 6 weeks and, when tension is substantial, for up to 6 months. Surgical techniques, such as W-plasty and Z-plasty, improve the appearance and mobility of contracted burn scars but are not appropriate for immature hypertrophic scars.<sup>16</sup>

### *Corticosteroid Injections*

Despite relatively few randomized, prospective studies, there is a broad consensus that injected triamcinolone is efficacious and is first-line therapy for the treatment of keloids and second-line therapy for the treatment of hypertrophic scars if other easier treatments have not been efficacious.<sup>15,17-23</sup> Despite their use in scar management since the mid-1960s, their principal mechanism of action remains unclear.<sup>24,25</sup> Response rates vary from 50 to 100 percent, with a recurrence rate of 9 to 50 percent.<sup>18</sup> Results are improved when corticosteroids are combined with other therapies such as surgery<sup>11,13,26</sup> and cryotherapy.<sup>27,28</sup>

Intralesional corticosteroid injection is associated with significant injection pain, even with standard doses of insoluble triamcinolone (40

mg/ml), and up to 63 percent of patients experience side effects that include skin atrophy, depigmentation, and telangiectasias.<sup>29</sup> Topical steroid creams have been used with varying success,<sup>30</sup> but absorption through an intact epithelium into the deep dermis is limited. A prospective, randomized study shows that topical steroids do not reduce scar formation in postburn deformities.<sup>31</sup>

### *Silicone Gel Sheetting*

Silicone gel sheeting has been a widely used clinical management option for hypertrophic scars and keloids since the early 1980s.<sup>32-37</sup> Despite initial skepticism, there is now good evidence of its efficacy and silicone gel sheeting has now become standard care for plastic surgeons. Results from at least eight randomized, controlled trials and a meta-study of 27 trials<sup>38</sup> demonstrate that silicone gel sheeting is a safe and effective management option for hypertrophic scars and keloids.<sup>39-48</sup> Totally occlusive dressings (e.g., polyethylene films) and semi-occlusive dressings, such as polyurethane films, have not shown evidence of efficacy, and evidence of the effectiveness of other materials such as glycerin and other non-silicone-based dressing is mixed.<sup>49-51</sup>

Silicone gel sheeting may be especially useful in children and others who cannot tolerate the pain of other management procedures. Silicone products vary considerably in composition, durability, and adhesion. To date, most conclusive trials have been undertaken on pure adherent silicone gel sheeting. It is not known whether these results are transferable to other fabric/polyurethane dressings with silicone adhesive or to nonadherent silicone products.<sup>52</sup> Some formulations of silicone oil have been shown to be effective on minor hypertrophic scars, although these studies have limitations in their design.<sup>33,53</sup>

### *Pressure Therapy*

Pressure therapy has been used in the management of hypertrophic scars and keloids since the 1970s.<sup>54</sup> It has been standard therapy for hypertrophic burn scars and is still first-line therapy in many centers.<sup>55-61</sup>

It is generally recommended that pressure be maintained between 24 and 30 mmHg for 6 to 12 months for this therapy to be effective; however, this advice is largely empiric.<sup>18,62</sup> There are mixed reports on long-term compliance, but it remains a significant issue, as ef-

fectiveness seems to be related directly to the duration of pressure.<sup>63-65</sup>

The evidence supporting the speed of scar maturation and enhancement of cosmetic outcome is variable. For example, in a prospective randomized study in 122 burn patients, pressure garments did not increase the speed of wound maturation or decrease the duration of hospital stay.<sup>66</sup>

#### *Radiotherapy*

Radiotherapy has been used as monotherapy, and in combination with surgery, for hypertrophic scars and keloids. However, monotherapy remains controversial<sup>15,67</sup> because of anecdotal reports of carcinogenesis following the procedure. Response to radiotherapy alone is 10 to 94 percent, with a keloid recurrence rate of 50 to 100 percent.<sup>11,13</sup> Such high recurrence rates are understandable, given the resistance of these cases to other management options. Best results have been achieved with 1500 to 2000 rads over five to six sessions in the early postoperative period.<sup>68,69</sup> There have been mixed results from radiotherapy after surgical excision of keloids, with a significant objective response reported in 25 to 100 percent of patients.<sup>18,70,71</sup>

Radiotherapy is difficult to evaluate, as most studies are retrospective, do not define the term "recurrence," and use a variety of radiation techniques with varying follow-up (6 to 24 months). In addition, there are no randomized, prospective studies with long-term follow-up. Most investigators agree that radiotherapy should be reserved for adults and keloids resistant to other management modalities. Nevertheless, radiotherapy with informed consent remains a valuable therapeutic option and is the most efficacious treatment available in severe cases of keloids, provided there is appropriate shielding of nonaffected tissues.

#### *Laser Therapy*

Laser therapy has been used for nonspecific destruction of tissue to produce less scarring, but this has been largely discredited following mixed results in larger long-term trials with carbon dioxide and argon lasers. Carbon dioxide lasers showed early promise in the excision of keloids<sup>72</sup> but failed to suppress keloid growth and recurrence in later studies.<sup>73,74</sup>

Two newer types of carbon dioxide laser are in use. Small noncontrolled studies, limited by lack of long-term follow-up, suggested that

high-energy short-pulsed carbon dioxide lasers and scanned continuous-wave carbon dioxide lasers were effective in postsurgical hypertrophic/keloidal, traumatic, acne, and varicella scars.<sup>75,76</sup> Scanning carbon dioxide lasers have been used to debride burn wounds, but without clinically improved scar outcome.<sup>77</sup> However, these early reports have not been widely substantiated, and currently carbon dioxide laser is not widely accepted for the treatment of keloids because of the high late recurrence rates.

Argon lasers were first used in the 1970s for the management of keloids, but studies failed to show long-term improvements.<sup>73,78</sup> They produce more nonspecific thermal damage than carbon dioxide lasers and are associated with higher levels of keloid recurrence.<sup>76</sup>

More recent wavelength-specific lasers (yttrium-aluminum-garnet and pulsed-dye lasers) have been used to selectively ablate blood vessels. Neodymium:yttrium-aluminum-garnet lasers have response rates between 36 and 47 percent.<sup>79</sup> In a recent study of 17 patients with keloids, nearly 60 percent of keloids were flattened following one session of neodymium:yttrium-aluminum-garnet laser treatment. These patients remained free of keloid scarring at 18-month to 5-year follow-up.<sup>80</sup> The remaining seven patients required further laser treatment and intralesional corticosteroids to flatten the keloids completely. Recurrence of keloids occurred in three patients, all of whom responded to further laser treatment. A recent study in 36 patients has shown that the pulsed erbium:yttrium-aluminum-garnet laser is an effective and safe treatment option for hypertrophic and depressed scars.<sup>81</sup> Further large comparative studies with longer follow-up are now required.

Flashlamp-pumped pulsed-dye lasers have shown promise in elimination of erythema and flattening atrophic and hypertrophic scars.<sup>82-85</sup> Intense-pulsed-light-source devices are usually considered in the same category as pulsed-dye lasers. Improvements in appearance of hypertrophic scars and keloids have been noted in 57 to 83 percent of cases,<sup>82</sup> with further improvements seen in combination with intralesional corticosteroids.<sup>86</sup> A pilot study has suggested that laser treatment in combination with intralesional corticosteroids is effective in healing previously resistant keloids.<sup>87</sup> A recent study in 106 patients (171 anatomic sites) has shown fast resolution of scar stiffness and ery-

thema and improvement in quality of scarring when preventive treatment with flashlamp-pumped pulsed-dye lasers is started within 2 weeks after surgery.<sup>88</sup> However, a recent single-blind, randomized, controlled study in 20 patients with hypertrophic scars showed no improvements in hypertrophic scars following laser therapy.<sup>89</sup> Laser therapy remains emerging technology, with limited follow-up and a lack of controlled studies. Further studies are required to define its role. However, many dermatologists, and some of the authors, have seen benefits in erythematous hypertrophic scars in speeding resolution, and perhaps improving long-term outcomes.

#### *Cryotherapy*

Cryotherapy alone results in keloid flattening in 51 to 74 percent of patients after two or more sessions, and it is beneficial for the management of severe acne scars.<sup>90-93</sup> Limitations include the delay of several weeks required for postoperative healing and the commonly occurring side effect of permanent hypopigmentation. Other side effects include hyperpigmentation, moderate skin atrophy, and pain.<sup>94</sup> As a result, cryotherapy is generally limited to management of very small scars.

#### *Adhesive Microporous Hypoallergenic Paper Tape*

The consensus of the authors was that applying paper tape with an appropriate adhesive to fresh surgical incisions, and for several weeks after surgery, was useful. The mechanism of benefit is unknown, but may in part be mechanical (analogous to pressure therapy) and occlusive (analogous to silicone gel therapy). However, only two uncontrolled studies confirm its efficacy.<sup>95,96</sup> The authors also felt that this treatment was less effective than more established treatments such as silicone gel, but it could be used as preventive treatment in low-risk patients, or before silicone gel use in fresh incisions. Tape with an elastic component may be useful for scars over mobile or complex surfaces, including joints.

#### *Miscellaneous Therapies*

There are anecdotal reports on a number of additional therapies, but there is no adequate published information on which the authors can evaluate the efficacy and safety of these therapies or make recommendations. These therapies fall into three categories.

The first category includes popular treat-

ments that have an absence of randomized studies or some negative studies suggesting lack of efficacy. These include topical vitamin E,<sup>31,97,98</sup> onion extract cream,<sup>99</sup> allantoin-sulfomucopolysaccharide gel,<sup>100,101</sup> glycosaminoglycan gel,<sup>102</sup> and creams containing extracts from plants such as *Bulbine frutescens* and *Centella asiatica*.<sup>103</sup>

The second category includes classic therapies with anecdotal success but significant side effects or lack of confirming studies. These include topical retinoic acid,<sup>104</sup> colchicine,<sup>105</sup> and systemic antihistamines.<sup>106</sup>

The third category includes newer therapies with anecdotal reports that do not yet have a history. Although these may develop into useful therapies in the future, the authors cannot make any recommendations at this time. These include skin equivalents that incorporate artificial dermis constructs, cyclosporine,<sup>107</sup> and intralesional verapamil.<sup>108</sup>

Other physical management options include hydrotherapy, massage, ultrasound, static electricity, and pulsed electrical stimulation. Hydrotherapy is widely used in several European countries for the treatment of hypertrophic burn scars (using high pressure). Massage has been widely used by physical therapists, occupational therapists, and other allied health care professions. However, further long-term studies are required before recommendations can be made regarding their efficacy.

#### *Emerging Evidence*

Three therapies provide emerging evidence of efficacy:

- Interferon (interferon- $\alpha$ , interferon- $\beta$ , and interferon- $\gamma$ )<sup>109-115</sup>
- Intralesional 5-fluorouracil<sup>115,116</sup>
- Bleomycin injections<sup>117-120</sup>

Interferon- $\alpha$ , interferon- $\beta$ , and interferon- $\gamma$  have been shown to increase collagen breakdown.<sup>109-111</sup> Tredget et al. found that interferon- $\alpha$ 2b injections three times weekly resulted in significant mean rates of improvement of hypertrophic scars versus control and also reduced serum transforming growth factor- $\beta$  levels that continued after treatment.<sup>114</sup> Interferon injections are reported to be significantly better than triamcinolone acetonide injections in preventing postsurgical recurrence of keloids (18.7 percent versus 58.5 percent recur-

rence).<sup>115</sup> However, these painful injections may require regional anesthesia.

Intralesional 5-fluorouracil has been used successfully as monotherapy as well as in combination with intralesional corticosteroids to treat hypertrophic scars and keloids.<sup>15,116</sup> Physicians experienced in its use show great enthusiasm for 5-fluorouracil. The rationale for its use is sound, and it shows a lack of side effects. It may warrant further investigation and wider use as an alternative to steroid injections in difficult-to-treat patients.

Bleomycin injections show evidence of efficacy in managing surgical/traumatic hypertrophic scars.<sup>117,118</sup> Patients with older scars resistant to intralesional corticosteroids showed good response to bleomycin 0.01% injections every 3 to 4 weeks. A recent pilot study in 13 patients showed complete flattening (six patients) or significant flattening (>90 percent; six patients) of hypertrophic scars and keloids following administration of bleomycin (1.5 IU/ml) using a multiple-puncture method on the skin surface.<sup>119</sup> Although published research is limited, there is considerable clinical experience in using this modality in some European countries. The rationale for use of bleomycin, which is another chemotherapeutic agent, is similar to that of 5-fluorouracil. A comparative study of the two agents with steroids is warranted. Adverse effects have not been reported for this indication, although side effects in the treatment of warts with bleomycin include nail loss and Raynaud's phenomenon.<sup>120,121</sup>

Bleomycin and intralesional 5-fluorouracil have been used by some of the authors with considerable success. Despite a strong theoretical rationale, larger scale prospective studies with appropriate follow-up are needed before these treatments can be considered as standard therapy.

In addition, experimental animal studies suggest that there may be a role for transforming growth factor modulators.<sup>122-125</sup> Transforming growth factor- $\beta$  has been implicated in several scarring conditions including pulmonary fibrosis, glomerulonephritis, and cutaneous scarring. There are three isoforms, and there is some evidence that the ratio is critical for optimizing scar outcome. In addition to blocking transforming growth factor- $\beta$  effects with antibodies, researchers have proposed blocking transforming growth factor- $\beta$  activation by means of the mannose 6-phosphate receptor,

and adding the transforming growth factor- $\beta$  isoform. These approaches have shown efficacy in animal models.<sup>125-127</sup> Early human trials are in progress for some of these strategies.

Another area of active research is interference with collagen synthesis. Historically, penicillamine and other nonspecific inhibitors of collagen synthesis were used as inhibitors, but they showed unacceptable toxicity. In recent years, several companies have looked for specific nontoxic inhibitors of collagen synthesis that could be applied locally. Animal trials have been promising.<sup>128</sup> Overall, there has been a substantial effort in the pharmaceutical and biotechnology industry to develop more effective anticarring therapies, and it seems likely that new therapies will be available within the next 5 years.

#### RECOMMENDATIONS

These recommendations are made primarily on the basis of the clinical evidence reviewed above and reflect the practice of the authors and have been summarized in simple management algorithms (Figs. 1 and 2). Cost-effectiveness of therapies is not assessed in this article.

#### *Prevention*

Every effort must be made to prevent the development of hypertrophic scars or keloids after surgery or trauma. Excellent surgical technique and efforts to prevent postsurgical infection are of prime importance.<sup>129</sup> Special attention should be given to high-risk patients (i.e., those who have previously suffered abnormal scarring or are undergoing a procedure with a high incidence of scarring, such as breast and thoracic surgery). To our knowledge, there has been no large-scale assessment of scar outcomes and risk factors. Recommended preventive techniques include the following:

- Hypoallergenic microporous tape with elastic properties to minimize the risk from shearing. Use of taping for a few weeks after surgery is standard practice for the majority of the authors. Although there are no prospective controlled studies documenting its efficacy, the authors' consensus is that it is beneficial.
- Silicone gel sheeting, which should be considered as first-line prophylaxis. Use of silicone gel sheeting should begin soon after surgical closure, when the incision has fully

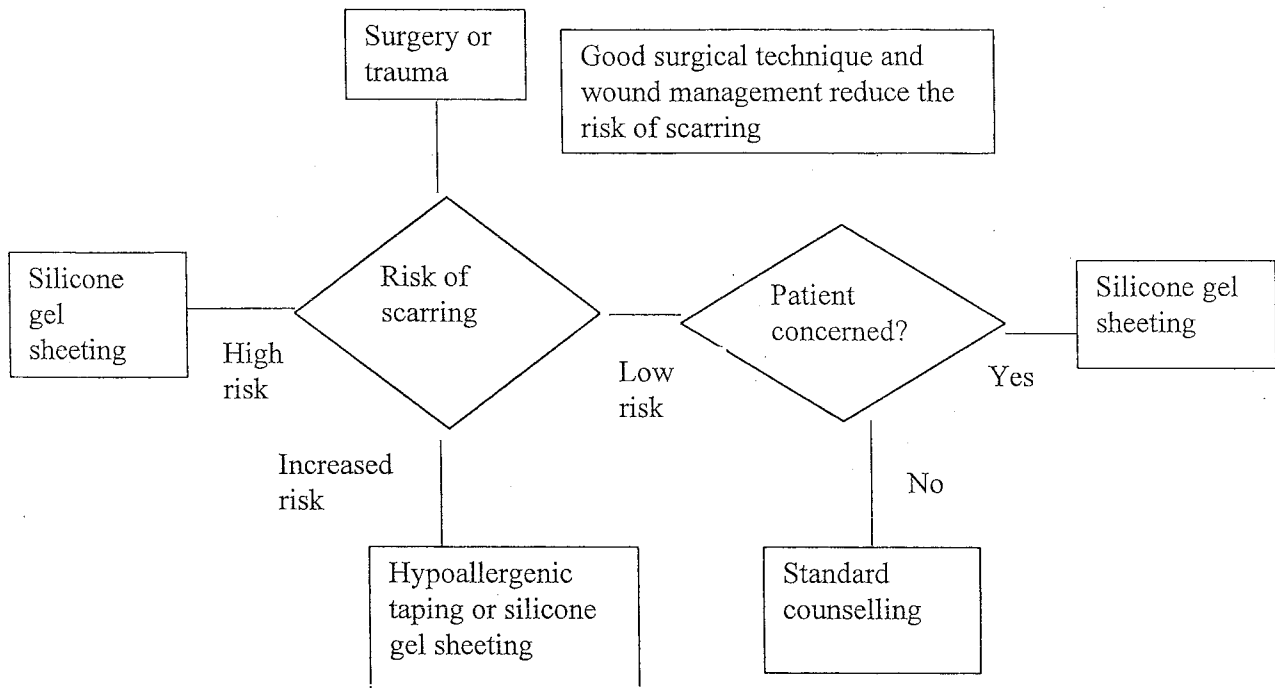


FIG. 1. Prevention of surgical/trauma scarring.

epithelialized, and be continued for at least 1 month. Silicone gel sheets should be worn for a minimum of 12 hours daily, and if possible for 24 hours per day, with twice-daily washing. Use of silicone ointments may be appropriate on the face and neck regions, although their efficacy in preventing scarring is unsupported by controlled trials.

- Concurrent intralesional corticosteroid injections as second-line prophylaxis for more severe cases.

The effectiveness of alternative therapies is limited to anecdotal evidence. Patients at low risk of scarring should maintain normal hygiene procedures and be provided with counseling and advice if concerned about their scar.

#### Scar Classification and Patient History

When patients present with a troublesome scar, appropriate therapy should be selected on the basis of scar classification and patient history. Scar classification is the primary decision criterion for treatment selection. Patient history, however, provides important information about the risk of the scar worsening should treatment fail, about previous therapies, and about the patient's likely compliance. The degree of erythema has been identified as being of great importance in predicting the activity of the scar and response to therapy.

#### Associated Symptoms

Pain and itchiness are commonly reported symptoms associated with scarring. Evidence of management methodologies for pruritus remains anecdotal. Pulsed-dye lasers may have value in reduction of itching, although more cost-effective options are preferred at this stage. Other treatments, such as moisturizers, silicone gel sheeting, systemic antihistamines, topical corticosteroids, antidepressants, massage, and hydrotherapy have been shown to improve symptoms. Care should be taken with hypersensitivity to moisturizing products such as lanolin.

#### Management

*Immature hypertrophic scars (red).* It is often difficult to predict whether this type of scar will resolve or develop into a hypertrophic scar. In the authors' experience, the techniques described above in the Prevention section should be followed. If erythema persists for more than 1 month, the risk of true hypertrophy increases and management should be as for a linear or widespread hypertrophic scar as appropriate (see below). These scars may benefit from a course of pulsed-dye laser therapy, although this therapy requires further long-term trials.

*Linear hypertrophic (surgical/traumatic) scars (red, raised).* Silicone gel sheeting should be

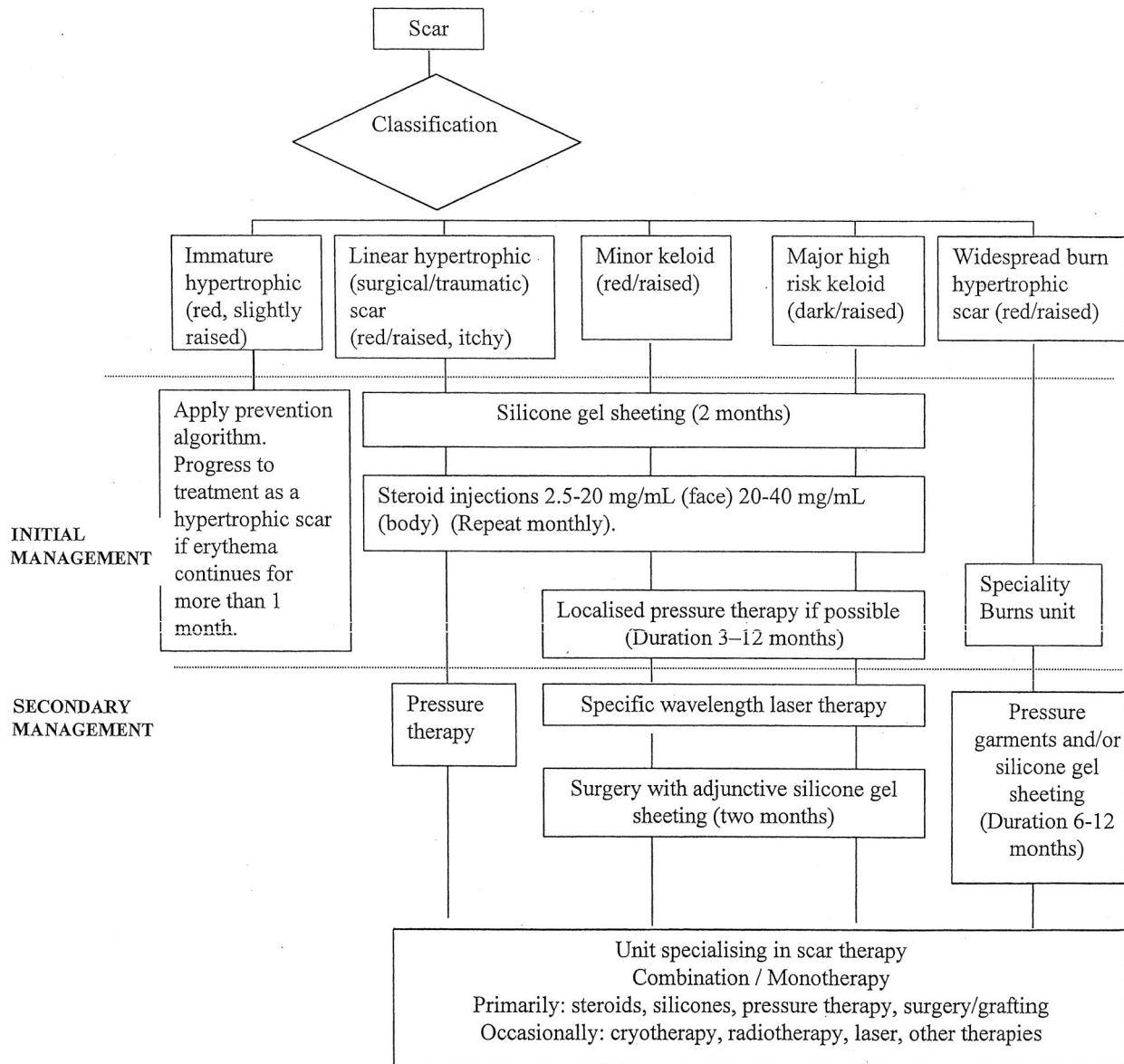


FIG. 2. Complete management algorithm.

used as first-line therapy, in line with results from randomized, controlled trials. If the scar is resistant to silicone therapy, or the scar is more severe and pruritic, further management with corticosteroid injections is indicated. Additional consideration may be given to other second-line therapies mentioned above for severe cases.

If silicone gel sheeting, pressure garments, and intralesional corticosteroid injections are not successful after 12 months of conservative therapy, surgical excision with postoperative application of silicone gel sheeting should be considered. An option for more severe scars is reexcision with layering of triamcinolone ace-

tonide, long-term placement of intradermal sutures, and subsequent corticosteroids. Specific-wavelength laser therapy and cryotherapy have been used by the authors but require further controlled studies.

*Widespread burn hypertrophic scars (red/raised).* Widespread burn scars should be treated with first-line therapy of silicone gel sheeting and pressure garments, although there remains limited significant evidence for the efficacy of pressure garments. The treatment of burn scars is difficult and often requires a combination of techniques including individualized pressure therapy; massage and/or physical therapy; silicone gel sheeting; corticosteroids on particu-



larly difficult areas; and surgical procedures such as Z-plasty, excision, and grafting or flap coverage. A variety of adjunctive therapies such as massage, hydrocolloids, and antihistamines to relieve pruritus are also used. Pulsed-dye laser may have a role.

*Minor keloids.* The consensus view from the literature and the authors is that first-line therapy for most minor keloids is a combination of silicone gel sheeting and intralesional corticosteroids. If there is no resolution, surgical excision with follow-up intralesional steroids and silicone gel sheeting is indicated. Localized pressure therapy such as ear clips on earlobe keloids has been shown to be helpful as second-line adjunctive therapy in small trials.

Surgical excision without careful follow-up or use of other adjunctive measures will result in a high recurrence rate, and if the surgery is performed without careful attention to preserving normal architecture, the resulting deformity after recurrence may be worse. It is preferable to only partially excise the keloid rather than produce a deformity. The authors' experience is that excision of difficult recurrent keloids with grafting of skin taken from the excised keloid followed by immediate radiation therapy can be successful, but that the long-term risks of radiation must be carefully weighed.

*Major keloids.* Major keloids are a most challenging clinical problem, and many are resistant to any treatment. Extensive counseling with the patient is required before embarking on a surgical solution because the recurrence rate is so high. For some patients, symptomatic treatment with antihistamines and good hygiene may be all that is possible. Radiation therapy should be considered for treatment failures, and innovative therapies such as bleomycin and 5-fluorouracil may have a future role, in addition to investigational strategies that interfere with transforming growth factor- $\beta$  or collagen synthesis. These patients are best treated by clinicians with a special interest in keloids. Ongoing patient counseling and advice on prevention are essential components of this therapy.

#### CONCLUSIONS

Management choices should depend on the patient's individual requirements and evidence-based findings. There remains a significant need for further randomized, controlled trials of all available scar therapies and system-

atic, quantitative reviews of the literature to ensure optimal management of scarring. The authors' recommendations are made on the basis of the best available evidence in the literature, particularly randomized, controlled trials, supported by clinical experience. Many management techniques have limited data to support their use, and these recommendations support a move to a more evidence-based approach in scar management.

*Thomas A. Mustoe, M.D.*

*Division of Plastic and Reconstructive Surgery  
Northwestern University School of Medicine  
675 North Saint Clair, 19-250  
Chicago, Ill. 60611  
tmustoe@nmh.org*

#### ACKNOWLEDGMENTS

Editorial assistance has been provided by Jeremy Bray. A small unrestricted educational grant was provided by Smith & Nephew Medical, Ltd., and used by the panel for coordination and communication.

#### REFERENCES

1. Guyatt, G. H., Sackett, D. L., Sinclair, J. C., et al. User's guides to the medical literature: IX. A method for grading healthcare recommendations. *J.A.M.A.* 274: 1800, 1995.
2. Piantadosi, S. David Byar as a teacher. *Control. Clin. Trials* 16: 202, 1995.
3. Olkin, I. Statistical and theoretical considerations in meta-analysis. *J. Clin. Epidemiol.* 48: 133, 1995.
4. Davey, R. B., Sprod, R. T., and Neild, T. O. Computerised colour: A technique for the assessment of burn scar hypertrophy. A preliminary report. *Burns* 25: 207, 1999.
5. Powers, P. S., Sarkar, S., Goldgof, D. B., Cruse, C. W., and Tsap, L. V. Scar assessment: Current problems and future solutions. *J. Burn Care Rehabil.* 20: 54, 1999.
6. Beausang, E., Floyd, H., Dunn, K. W., Orton, C. I., and Ferguson, M. W. A new quantitative scale for clinical scar assessment. *Plast. Reconstr. Surg.* 102: 1954, 1998.
7. Yeong, E. K., Mann, R., Engrav, L. H., et al. Improved burn scar assessment with use of a new scar-rating scale. *J. Burn Care Rehabil.* 18: 353, 1997.
8. Sullivan, T., Smith, J., Kermodie, J., et al. Rating the burn scar. *J. Burn Care Rehabil.* 11: 256, 1990.
9. Baryza, M. J., and Baryza, G. A. The Vancouver Scar Scale: An administration tool and its interrater reliability. *J. Burn Care Rehabil.* 16: 535, 1995.
10. Nedelec, B., Shankowsky, A., and Tredgett, E. E. Rating the resolving hypertrophic scar: Comparison of the Vancouver Scar Scale and scar volume. *J. Burn Care Rehabil.* 21: 205, 2000.
11. Berman, B., and Bielewicz, H. C. Adjunct therapies to surgical management of keloids. *Dermatol. Surg.* 22: 126, 1996.
12. Darzi, M. A., Chowdri, N. A., Kaul, S. K., et al. Evaluation of various methods of treating keloids and hypertrophic scars: A 10-year follow-up study. *Br. J. Plast. Surg.* 45: 374, 1992.
13. Lawrence, W. T. In search of the optimal treatment of

- keloids: Report of a series and a review of the literature. *Ann. Plast. Surg.* 27: 164, 1991.
14. Berman, B., and Bieley, H. C. Keloids. *J. Am. Acad. Dermatol.* 33: 117, 1995.
  15. Urioste, S. S., Arndt, K. A., and Dover, J. S. Keloids and hypertrophic scars: Review and treatment strategies. *Semin. Cutan. Med. Surg.* 18: 159, 1999.
  16. Sherris, D. A., Larrabee, W. F., Jr., and Murakami, C. S. Management of scar contractures, hypertrophic scars and keloids. *Otolaryngol. Clin. North Am.* 28: 1057, 1995.
  17. Rockwell, W. B., Cohen, I. K., and Ehrlich, H. P. Keloids and hypertrophic scars: A comprehensive review. *Plast. Reconstr. Surg.* 84: 827, 1989.
  18. Niessen, F. B., Spauwen, P. H. M., Schalkwijk, J., and Kon, M. On the nature of hypertrophic scars and keloids: A review. *Plast. Reconstr. Surg.* 104: 1435, 1999.
  19. Alster, T. S., and West, T. B. Treatment of scars: A review. *Ann. Plast. Surg.* 39: 418, 1997.
  20. Murray, J. C. Keloids and hypertrophic scars. *Clin. Dermatol.* 12: 27, 1994.
  21. Kelly, A. P. Keloids. *Dermatol. Clin.* 6: 413, 1988.
  22. Murray, J. C. Scars and keloids. *Dermatol. Clin.* 11: 697, 1993.
  23. Griffith, B. H., Monroe, C. W., and McKinney, P. A follow-up study on the treatment of keloids with triamcinolone acetonide. *Plast. Reconstr. Surg.* 46: 145, 1970.
  24. McCoy, B. J., Diegelmann, R. F., and Cohen, I. K. In vitro inhibition of cell growth, collagen synthesis and prolyl hydroxylase activity by triamcinolone acetonide. *Proc. Soc. Exp. Biol. Med.* 163: 216, 1980.
  25. Ketchum, L. D., Smith, J., Robinson, D. W., et al. The treatment of hypertrophic scar, keloid and scar contracture by triamcinolone acetonide. *Plast. Reconstr. Surg.* 38: 209, 1966.
  26. Tang, Y. W. Intra- and postoperative steroid injections for keloids and hypertrophic scars. *Br. J. Plast. Surg.* 45: 371, 1992.
  27. Hirshowitz, B., Lerner, D., and Moscona, A. R. Treatment of keloid scars by combined cryosurgery and intralesional corticosteroids. *Aesthetic Plast. Surg.* 6: 153, 1982.
  28. Whang, K. K., Park, H. J., and Myung, K. B. The clinical analysis of the combination of cryosurgery and intralesional corticosteroid for keloid or hypertrophic scars. *Korean J. Dermatol.* 35: 450, 1997.
  29. Sproat, J. E., Dalcin, A., Weitauer, N., and Roberts, R. S. Hypertrophic sternal scars: Silicone gel sheeting versus kenalog injection treatment. *Plast. Reconstr. Surg.* 90: 988, 1992.
  30. Yii, N. W., and Frame, J. D. Evaluation of cythasquin and topical steroid in the treatment of hypertrophic scars and keloids. *Eur. J. Plast. Surg.* 19: 162, 1996.
  31. Jenkins, M., Alexander, J. W., MacMillan, B. G., et al. Failure of topical steroids and vitamin E to reduce postoperative scar formation following reconstructive surgery. *J. Burn Care Rehabil.* 7: 309, 1986.
  32. Perkins, K., Davey, R. B., and Wallis, K. A. Silicone gel: A new treatment for burn scars and contractures. *Burns Incl. Therm. Inj.* 9: 201, 1983.
  33. Sawada, Y., and Sone, K. Treatment of scars and keloids with a cream containing silicone oil. *Br. J. Plast. Surg.* 43: 683, 1990.
  34. Chang, C. C., Kuo, Y. F., Chiu, H., et al. Hydration, not silicone, modulates the effects of keratinocytes on fibroblasts. *J. Surg. Res.* 59: 705, 1995.
  35. Carney, S. A., Cason, C. G., Gowar, J. P., et al. Cica-care gel sheeting in the management of hypertrophic scarring. *Burns* 20: 163, 1994.
  36. Branagan, M., Chenery, D. H., and Nicholson, S. Use of the infrared attenuated total reflectance spectroscopy for the in vivo measurement of hydration level and silicone distribution in the stratum corneum following skin coverage by polymeric dressings. *Skin Pharmacol. Appl. Skin Physiol.* 13: 157, 2000.
  37. Suetake, T., Sasai, S., Zhen, Y.-X., and Tagami, H. Effects of silicone gel sheet on the stratum corneum hydration. *Br. J. Plast. Surg.* 53: 503, 2000.
  38. Poston, J. The use of silicone gel sheeting in the management of hypertrophic and keloid scars. *J. Wound Care* 9: 10, 2000.
  39. Su, C. W., Alizadeh, K., Boddie, A., and Lee, R. C. The problem scar. *Clin. Plast. Surg.* 25: 451, 1998.
  40. Katz, B. E. Silicone gel sheeting in scar therapy. *Cutis* 56: 65, 1995.
  41. Berman, B., and Flores, F. Comparison of a silicone gel-filled cushion and silicone gel sheeting for the treatment of hypertrophic or keloid scars. *Dermatol. Surg.* 25: 484, 1999.
  42. Gold, M. H. A controlled clinical trial of topical silicone gel sheeting in the treatment of hypertrophic scars and keloids. *J. Am. Acad. Dermatol.* 30: 506, 1994.
  43. Cruz-Korchin, N. I. Effectiveness of silicone sheets in the prevention of hypertrophic breast scars. *Ann. Plast. Surg.* 37: 345, 1996.
  44. Agarwal, U. S., Jain, D., Gulati, R., et al. Silicone gel sheet dressings for prevention of post-minigraft cobblestoning in vitiligo. *Dermatol. Surg.* 25: 102, 1999.
  45. Ahn, S. T., Monafo, W. W., and Mustoe, T. A. Topical silicone gel for the prevention and treatment of hypertrophic scars. *Arch. Surg.* 126: 499, 1991.
  46. Ahn, S. T., Monafo, W. W., and Mustoe, T. A. Topical silicone gel: A new treatment for hypertrophic scars. *Surgery* 106: 781, 1989.
  47. Gold, M. H. The role of CICA-CARE in preventing scars following surgery: A review of hypertrophic and keloid scar treatments. Oral presentation at the Annual Meeting of the American Academy of Dermatology, San Francisco, Calif., March 10–15, 2000.
  48. Borgognoni, L., Martini, L., Chiarugi, C., Gelli, R., and Reali, U. M. Hypertrophic scars and keloids: Immunophenotypic features and silicone sheets to prevent recurrences. *Ann. Burns Fire Disasters* 8: 164, 2000.
  49. Quinn, K. J. Silicone gel in scar treatment. *Burns* 13: S33, 1987.
  50. Morris, D. E., Wu, L., Zhao, L. L., et al. Acute and chronic animal models for excessive dermal scarring: Quantitative studies. *Plast. Reconstr. Surg.* 100: 674, 1997.
  51. Baum, T. M., and Busuito, M. J. Use of a glycerin-based gel sheeting in scar management. *Adv. Wound Care* 11: 40, 1998.
  52. Phillips, T. J., Gerstein, A. D., Lordan, V., et al. A randomized controlled trial of hydrocolloid dressing in the treatment of hypertrophic scars and keloids. *Dermatol. Surg.* 22: 775, 1996.
  53. Wong, T. W., Chiu, H. C., Chang, C. H., et al. Silicone cream occlusive dressing: A novel non-invasive regimen in the treatment of keloid. *Dermatology* 192: 329, 1996.
  54. Staley, M. J., and Richard, R. L. Use of pressure to treat hypertrophic burn scars. *Adv. Wound Care* 10: 44, 1997.

55. Fricke, N. B., Omnell, M. L., Dutcher, K. A., Hollender, L. G., and Engrav, L. H. Skeletal and dental disturbances in children after facial burns and pressure garment use: A 4-year follow-up. *J. Burn Care Rehabil.* 20: 239, 1999.
56. Ward, R. S. Pressure therapy for the control of hypertrophic scar formation after burn injury: A history and review. *J. Burn Care Rehabil.* 12: 257, 1991.
57. Tredget, E. E. Management of the acutely burned upper extremity. *Hand Clin.* 16: 187, 2000.
58. Nedelec, B., Ghahary, A., Scott, P., and Tredget, E. Control of wound contraction: Basic and clinical features. *Hand Clin.* 16: 289, 2000.
59. Agrawal, K., Panda, K. N., and Arumugam, A. An inexpensive self-fabricated pressure clip for the ear lobe. *Br. J. Plast. Surg.* 51: 122, 1998.
60. Linares, H. A. From wound to scar. *Burns* 22: 339, 1996.
61. Rayner, K. The use of pressure therapy to treat hypertrophic scarring. *J. Wound Care* 9: 151, 2000.
62. Tilley, W., McMahon, S., and Shukalak, B. Rehabilitation of the burned upper extremity. *Hand Clin.* 16: 303, 2000.
63. Johnson, J., Greenspan, B., Gorga, D., et al. Compliance with pressure garment use in burn rehabilitation. *J. Burn Care Rehabil.* 15: 180, 1994.
64. Kealey, G. P., Jensen, K. L., Laubenthal, K. N., and Lewis, R. W. Prospective randomised comparison of two types of pressure therapy garments. *J. Burn Care Rehabil.* 11: 334, 1990.
65. Rose, M. P., and Deitch, E. A. The clinical use of a tubular compression bandage, Tubigrip, for burn scar therapy: A critical analysis. *Burns Incl. Therm. Inj.* 12: 58, 1985.
66. Chang, P., Laubenthal, K. N., Lewis, R. W., II, et al. Prospective, randomized study of the efficacy of pressure garment therapy in patients with burns. *J. Burn Care Rehabil.* 16: 473, 1995.
67. Norris, J. E. C. Superficial X-ray therapy in keloid management: A retrospective study of 24 cases and literature review. *Plast. Reconstr. Surg.* 95: 1051, 1995.
68. Cosman, B., Crikelair, G. F., Ju, D. M., et al. The surgical treatment of keloids. *Plast. Reconstr. Surg.* 27: 335, 1961.
69. Brown, L. A., Jr., and Pierce, H. E. Keloids: Scar revision. *J. Dermatol. Surg. Oncol.* 12: 51, 1986.
70. Levy, D. S., Salter, M. M., and Roth, R. E. Postoperative irradiation in the prevention of keloids. *A.J.R. Am. J. Roentgenol.* 127: 509, 1976.
71. Edsmyr, F., Larson, L. G., Onyango, J., et al. Radiotherapy in the treatment of keloids in East Africa. *East Afr. Med. J.* 50: 457, 1973.
72. Bailin, P. Use of the CO<sub>2</sub> laser for non-PWS cutaneous lesions. In K. A. Arndt, J. M. Noe, and S. Rosen (Eds.), *Cutaneous Laser Therapy: Principles and Methods*. New York: John Wiley, 1983. Pp. 187-200.
73. Apfelberg, D. B., Maser, M. R., White, D. N., et al. Failure of carbon dioxide laser excision of keloids. *Lasers Surg. Med.* 9: 382, 1989.
74. Norris, J. E. The effect of carbon dioxide laser surgery on the recurrence of keloids. *Plast. Reconstr. Surg.* 87: 44, 1991.
75. Bernstein, L. J., Kauvar, A. N., Grossman, M. C., et al. Scar resurfacing with high-energy short-pulsed and flash scanning carbon dioxide lasers. *Dermatol. Surg.* 24: 101, 1998.
76. Kantor, G. R., Wheeland, R. G., Bailin, P. L., et al. Treatment of earlobe keloids with carbon dioxide laser excision: A report of 16 cases. *J. Dermatol. Surg. Oncol.* 11: 1063, 1985.
77. Sheridan, R. L., Lydon, M. M., Petras, L. M., et al. Laser ablation of burns: Initial clinical trial. *Surgery* 125: 92, 1999.
78. Hulsbergen-Henning, J. P., Roskam, Y., and van Gemert, M. J. Treatment of keloids and hypertrophic scars with an argon laser. *Lasers Surg. Med.* 6: 72, 1986.
79. Abergel, R. P., Meeker, C. A., Lam, T. S., and Dwyer, R. M. Control of connective tissue metabolism by lasers: Recent developments and future prospects. *J. Am. Acad. Dermatol.* 11: 1142, 1984.
80. Kumar, K., Kapoor, B. S., Rai, P., and Shukla, H. S. In situ irradiation of keloid scars with Nd:YAG laser. *J. Wound Care* 9: 213, 2000.
81. Kwon, S. D., and Kye, Y. C. Treatment of scars with a pulsed Er:YAG laser. *J. Cutan. Laser Ther.* 2: 27, 2000.
82. Alster, T. S. Improvement of erythematous and hypertrophic scars by the 585 nm flashlamp pulsed dye laser. *Ann. Plast. Surg.* 32: 186, 1994.
83. Alster, T. S., Kurban, A. K., Grove, G. L., et al. Alteration of argon induced scars by the pulsed dye laser. *Lasers Surg. Med.* 13: 368, 1993.
84. Alster, T. S., and Williams, C. M. Treatment of keloid sternotomy scars with 585 nm flashlamp-pumped pulsed-dye laser. *Lancet* 345: 1198, 1995.
85. Dierickx, C., Goldman, M. P., and Fitzpatrick, R. E. Laser treatment of erythematous/hypertrophic and pigmented scars in 26 patients. *Plast. Reconstr. Surg.* 95: 84, 1995.
86. Goldman, M., and Fitzpatrick, R. E. Laser treatment of scars. *Dermatol. Surg.* 21: 685, 1995.
87. Connell, P. G., and Harland, C. C. Treatment of keloid scars with pulsed dye lasers and intralesional steroid. *J. Cutan. Laser Ther.* 2: 147, 2000.
88. McCraw, J. B., McCraw, J. A., McMellin, A., and Bettencourt, N. Prevention of unfavorable scars using early pulse dye laser treatments: A preliminary report. *Ann. Plast. Surg.* 42: 7, 1999.
89. Wittenberg, G. P., Fabian, B. G., Bogomilsky, J. L., et al. Prospective single-blind, randomised controlled study to assess the efficacy of the 585-nm flashlamp pumped pulsed-dye laser and silicone gel sheeting in hypertrophic scar treatment. *Arch. Dermatol.* 135: 1049, 1999.
90. Layton, A. M., Yip, J., and Cunliffe, W. J. A comparison on intralesional triamcinolone and cryosurgery in the treatment of acne keloids. *Br. J. Dermatol.* 130: 498, 1994.
91. Ciampo, E., and Iurassich, S. Liquid nitrogen cryosurgery in the treatment of acne lesions. *Ann. Ital. Dermatol. Clin. Sper.* 51: 67, 1997.
92. Zouboulis, C., Blume, U., Buttner, P., and Orfanos, C. E. Outcomes of cryosurgery in keloids and hypertrophic scars: A prospective, consecutive trial of case series. *Arch. Dermatol.* 129: 1146, 1993.
93. Ernst, K., and Hundeiker, M. Results of cryosurgery in 394 patients with hypertrophic scars and keloids. *Hautarzt* 46: 462, 1995.
94. Rusciani, L., Rosse, G., and Bono, R. Use of cryotherapy in the treatment of keloids. *J. Dermatol. Surg. Oncol.* 19: 529, 1993.
95. Reiffel, R. S. Prevention of hypertrophic scars by long-term paper tape application. *Plast. Reconstr. Surg.* 96: 1715, 1995.

96. Davey, R. B., Wallis, K. A., and Bowering, K. Adhesive contact media: An update on graft fixation and burn scar management. *Burns* 17: 313, 1991.
97. Havlik, R. J. Vitamin E and wound healing: Safety and efficacy reports. *Plast. Reconstr. Surg.* 100: 1901, 1997.
98. Baumann, L. S., Spencer, J., and Klein, A. W. The effects of topical vitamin E on the cosmetic appearance of scars. *Dermatol. Surg.* 25: 311, 1999.
99. Jackson, B. A., Shelton, A. J., and McDaniel, D. H. Pilot study evaluating topical onion extract as treatment for postsurgical scars. *Dermatol. Surg.* 25: 267, 1999.
100. Scalvenzi, M., Delfino, S., and Sammarco, E. Post dermatological scars: Improvement after application with an allantoin and sulphomucopolysaccharide-based gel. *Ann. Ital. Dermatol. Clin. Sper.* 52: 132, 1998.
101. Magliaro, A., Gianfaldoni, R., and Cervadoro, G. Treatment of burn scars with a gel based on allantoin and sulfomucopolysaccharides. *G. Ital. Dermatol. Venereol.* 134: 153, 1999.
102. Boyce, D. E., Bantick, G., and Murison, M. S. The use of ADCON-T/N glycosaminoglycan gel in the revision of tethered scars. *Br. J. Plast. Surg.* 53: 403, 2000.
103. Widgerow, A. D., Chait, L. A., Stals, R., and Stals, P. J. New innovations in scar management. *Aesthetic Plast. Surg.* 24: 227, 2000.
104. Janssen de Limpens, A. M. P. The local treatment of hypertrophic scars and keloids with topical retinoic acid. *Br. J. Dermatol.* 103: 319, 1980.
105. Peacock, E. E., Jr. Pharmacologic control of surface scarring in human beings. *Ann. Surg.* 193: 592, 1981.
106. Topol, B. M., Lewis, V. L., Jr., and Beneviste, K. The use of antihistamine to retard the growth of fibroblasts derived from human skin, scar and keloids. *Plast. Reconstr. Surg.* 68: 227, 1981.
107. Duncan, J. L., Thomson, A. W., and Muir, L. F. K. Topical cyclosporin and T-lymphocytes in keloid scars. *Br. J. Dermatol.* 124: 109, 1991.
108. Lawrence, W. T. Treatment of earlobe keloids with surgery plus adjuvant intralesional verapamil and pressure earrings. *Ann. Plast. Surg.* 37: 167, 1996.
109. Tredget, E. E., Wang, R., Shen, Q., Scott P. G., and Ghahary, A. Transforming growth factor-beta mRNA and protein in hypertrophic scar tissues and fibroblasts: Antagonism by IFN-alpha and IFN-gamma in vitro and in vivo. *J. Interferon Cytokine Res.* 20: 143, 2000.
110. Granstein, R. D., Rook, A., Flotte, T. J., et al. Controlled trial of intralesional recombinant interferon- $\gamma$  in the treatment of keloidal scarring. *Arch. Dermatol.* 126: 1295, 1990.
111. Pittet, B., Rubbia-Brandt, L., Desmoulieve, A., et al. Effect of gamma interferon on the clinical and biological evolution of hypertrophic scars and Dupuytren's disease: An open pilot study. *Plast. Reconstr. Surg.* 93: 1224, 1994.
112. Larrabee, W. F., Jr., East, C. A., Jaffe, H. S., et al. Intralesional interferon gamma treatment for keloids and hypertrophic scars. *Arch. Otolaryngol. Head Neck Surg.* 116: 1159, 1990.
113. Takeuchi, M., Tredget, E. E., Scott, P. G., Kilani, R. T., and Ghahary, A. The antifibrogenic effects of liposome-encapsulated IFN-alpha2b cream on skin wounds. *J. Interferon Cytokine Res.* 19: 1413, 1999.
114. Tredget, E. E., Shankowsky, H. A., Pannu, R., et al. Transforming growth factor-beta in thermally injured patients with hypertrophic scars: Effects of interferon alpha-2b. *Plast. Reconstr. Surg.* 102: 1317, 1998.
115. Berman, B., and Flores, F. Recurrence rates of excised keloids treated with postoperative triamcinolone acetate injections of interferon alfa-2b injections. *J. Am. Acad. Dermatol.* 37: 755, 1997.
116. Fitzpatrick, R. E. Treatment of inflamed hypertrophic scars using intralesional 5-FU. *Dermatol. Surg.* 25: 224, 1999.
117. Bodokh, I., and Brun, P. Traitement des chéloïdes par infiltrations de Bléomycine. *Ann. Dermatol. Venereol.* 123: 791, 1996.
118. Larouy, J. C. Traitement des chéloïdes: trois méthodes. *Nouv. Dermatol.* 19: 295, 2000.
119. Espana, A., Solano, T., and Quintanilla, E. Bleomycin in the treatment of keloids and hypertrophic scars by multiple needle punctures. *Dermatol. Surg.* 27: 23, 2001.
120. Smith, E. A., Harper, F. E., and LeRoy, E. C. Raynaud's phenomenon of a single digit following local intra-dermal bleomycin sulfate injection. *Arthritis Rheum.* 28: 459, 1985.
121. Epstein, E. Persisting Raynaud's phenomenon following intralesional bleomycin treatment of finger warts. *J. Am. Acad. Dermatol.* 13: 468, 1985.
122. O'Kane, S., and Ferguson, M. W. Transforming growth factor beta s and wound healing. *Int. J. Biochem. Cell Biol.* 29: 63, 1997.
123. Yamada, H., Tajima, S., Nishikawa, T., Murad, S., and Pinnell, S. R. Tranilast, a selective inhibitor of collagen synthesis in human skin fibroblasts. *J. Biochem. (Tokyo)* 116: 892, 1994.
124. Nakamura, K., Irie, H., Inoue, M., Mitani, H., Sunami, H., and Sano, S. Factors affecting hypertrophic scar development in median sternotomy incisions for congenital cardiac surgery. *J. Am. Coll. Surg.* 185: 218, 1997.
125. O'Kane, S., and Ferguson, M. W. Transforming growth factor betas and wound healing. *Int. J. Biochem. Cell Biol.* 29: 63, 1997.
126. Cowin, A. J., Holmes, T. M., Brosnan, P., and Ferguson, M. W. Expression of TGF-beta and its receptors in murine fetal and adult dermal wounds. *Eur. J. Dermatol.* 11: 424, 2001.
127. Tyrone, J. W., Marcus, J. R., Bonomo, S. R., Mogford, J. E., Xia, Y., and Mustoe, T. A. Transforming growth factor beta3 promotes fascial wound healing in a new animal model. *Arch. Surg.* 135: 1154, 2000.
128. Kim, I., Mogford, J. E., Witschi, C., Nafissi, M., and Mustoe, T. A. Inhibition of prolyl 4-hydroxylase reduces scar elevation in a rabbit model of hypertrophic scarring. *Wound Repair Regen.* 9: 139, 2001.
129. Harahap, M. *Surgical Techniques for Cutaneous Scar Revision*. New York: Marcel Dekker, 1999.